

An Unusual Case of Hepatosplenomegaly

BIGGS SARAVANAN RAMACHANDRAN

ABSTRACT

We are presenting here, an interesting case of a 4-year old girl who presented to our department with hepatosplenomegaly, fever, gum bleeding and oedema. She turned out to be a case of

osteopetrosis, which is a rare autosomal recessive inherited disorder. We should consider this disease as a differential diagnosis when we encounter hepatosplenomegaly and myelophthisic anaemia..

Key Words: Osteopetrosis, Myelophthisic anemia

INTRODUCTION

Osteopetrosis is an extremely rare, inherited disorder which is also called marble bone disease or the Albers Schonberg disease. The basic pathology in osteopetrosis is the defective resorption of bone by the osteoclasts. It can present in different ways; sometimes, the presentation is multi-systemic. Three types of osteopetrosis have been observed, namely the autosomal recessive, autosomal dominant and the carbonic anhydrase deficiency forms.

The autosomal recessive form presents during infancy. The autosomal dominant form typically presents during childhood or adolescence. A haematological presentation is one of the most common presentations in these patients, especially myelophthisic anaemia which presents with a reduction in the leukocytes, platelets and the red blood cells.

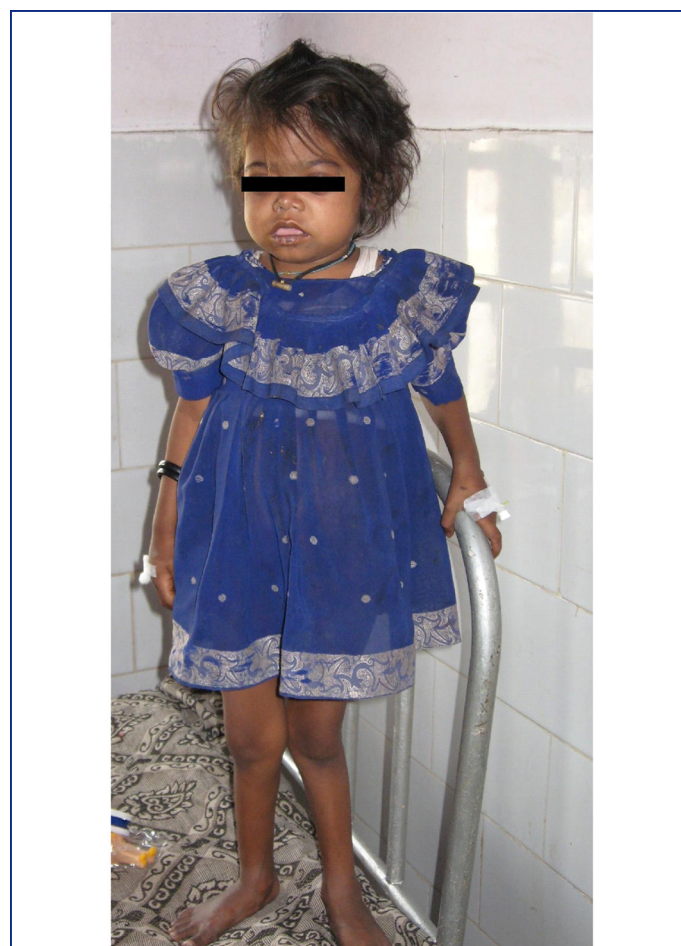CASE REPORT

A 4-year old girl [Table/Fig 1] presented to our department with easy fatigability for one month, bleeding from the gums during brushing of the teeth and fever of 4 days duration. She was born out of a non-consanguineous marriage. Her developmental milestones were normal. Her weight was 12 kilograms and her height was 110 cm.

On examination, she was found to have severe pallor and pedal oedema. She was febrile and tachypnoeic and she had hepatosplenomegaly. Her ENT evaluation showed mild conductive hearing loss. Her fundus examination showed normal findings. Her complete blood count showed a three cell line depression (Haemoglobin 4 gms% ; Total count - 2100; Platelet count- 45000).

The PA of her X ray chest view showed dense sclerotic bony shadows which were suggestive of osteopetrosis [Table/Fig 2]. The X rays of her skull showed a dense sclerotic shadow which was suggestive of the same disease [Table/Fig 3]. Her peripheral smear showed a leucoerythroblastic picture.

Her blood cultures did not show any growth. Her bone marrow aspiration ended in a dry tap twice. Based on these findings, myelophthisic anaemia which was secondary to osteopetrosis was made. Kala Azar was ruled out by the RK-39 test, as the patient

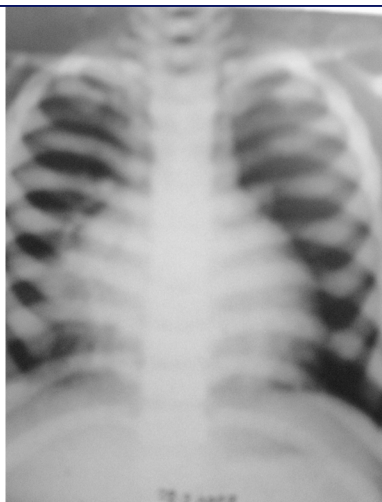


[Table/Fig-1]: Four year old girl with osteopetrosis having oedema of the legs and face.

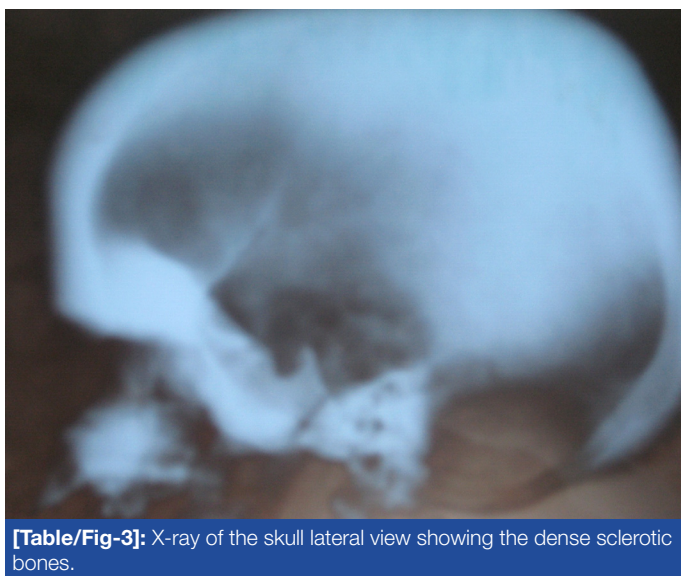was from a Kala Azar endemic zone. The patient was treated with packed cell transfusions and she was referred for bone marrow transplantation.

DISCUSSION

Osteopetrosis is an extremely rare inherited disorder which is also called marble bone disease or the Albers Schonberg disease. The basic pathological abnormality is failure of the osteoclasts to resorb



[Table/Fig-2]: X-ray chest showing the dense sclerotic bones involving ribs, vertebrae and clavicles.



[Table/Fig-3]: X-ray of the skull lateral view showing the dense sclerotic bones.

immature bone [1]. It causes abnormal formation of the medullary cavities, resulting in bone marrow failure. Abnormal resorption of the bones cause narrowed cranial nerve foraminas, resulting in various cranial nerve palsies, namely those of the optic, auditory and the facial nerves. Due to the abnormal remodelling of the bones, they are prone for repeated fractures. The types of osteopetrosis are namely, the type with an infantile onset or the autosomal recessive type; the adult onset or the autosomal dominant type and the carbonic anhydrase deficiency type. The presentation of the disease varies according to the type. The infantile onset disease usually presents within the first year of life. Visual impairment, failure to thrive, frequent infections and secondary bone marrow

involvement are the common presentations. The autosomal dominant type presents in childhood or adolescence with fractures, mild anaemia, bruising and cranial nerve palsies. Anaemia and hepatosplenomegaly with typical radiological pictures usually clinch the diagnosis [2]. Hepatosplenomegaly occurs due to extra-medullary haematopoiesis, as there is an abnormally narrowed medullary cavity. The characteristic radiological pictures are dense sclerotic bones, a bone within a bone appearance and a rugger jersey spine. A bone biopsy is not usually required unless the initial diagnosis is unclear or if the child's clinical progress varies significantly from the established phenotype. In such cases, a biopsy may prove beneficial [2]. Our case presented with anaemia, hepatosplenomegaly and fever, which could have been due to bone marrow failure, which is one of the most common presentations. Autosomal recessive osteopetrosis is a progressive disease and the survival at the age of 6 years is around 60% [3]. The therapeutic options are limited. Increased bone resorption, haematopoiesis and an improved leucocyte function were seen in the small number of patients who were studied with the use of recombinant interferon gamma-1b (1.5 µg/kg, three times per week) [4]. Bone marrow transplantation is the only treatment that can offer cure to these patients. 79% disease free survival has been observed in the HLA matched identical sibling donor transplantation as compared to the HLA mismatched related donor transplantation [5]. The indications for urgent bone marrow transplantation are sepsis and severe disease with an intact vision. Sepsis and bone marrow failure are the most common causes of death in osteopetrosis.

CONCLUSION

We should consider this disease as a differential diagnosis when we encounter hepatosplenomegaly and myelophthisic anaemia, although it is a rare disease.

REFERENCES

- [1] Flanagan AM, Sarma U, Steward CG, Vellodi A, Horton MA. Study of the non-resorptive phenotype of the osteoclast like cells from patients with malignant osteopetrosis: a new approach to investigating its pathogenesis. *J Bone Miner Res* 2000;15:352–60.
- [2] CJ Wilson, A Vellodi. Autosomal recessive osteopetrosis: diagnosis, management, and outcome. *Arch Dis Child* 2000;83:449–52.
- [3] Gerritsen EJA, Vossen JM, Van Loo IHG, Hermans J, Helfrich, MH Gris-cellii C. Autosomal recessive osteopetrosis. Variability of the findings at diagnosis and during the natural course. *Paediatrics* 1994;93:247–53.
- [4] Key LL, Rodriguiz RM, Willi SM, et al. Long term treatment of osteopetrosis with recombinant human interferon. *N Engl J Med* 1995;332:1594–9.
- [5] Gerritsen EJA, Vossen JM, Fasth A, et al. Bone marrow transplantation for osteopetrosis. A report from the Working Party on Inborn Errors of the European Bone Marrow Transplantation Group. *J Paediatr* 1994;125:896–902.

AUTHOR(S):

1. Dr. Biggs Saravanan Ramachandran

PARTICULARS OF CONTRIBUTORS:

1. Madras Medical College

NAME, ADDRESS, E-MAIL ID OF THE CORRESPONDING AUTHOR:

Dr. Biggs Saravanan Ramachandran
Room number 23, Old PG men's Hostel, Madras
Medical College, Park Town, Chennai- 600003, India.

FINANCIAL OR OTHER COMPETING INTERESTS:

None.

Date of Submission: Dec 28, 2011
Date of Peer review: Dec 29, 2011
Date of Acceptance: Jan 09, 2012
Date of Publishing: May 31, 2012